Anaplastic and other locally advanced thyroid carcinoma

Chung-Yau Lo, MS (HK), FRCS (Edin.), FACS
Professor and Chief of Endocrine Surgery
Department of Surgery
The University of Hong Kong
Queen Mary Hospital, Hong Kong

Thyroid carcinoma

Types and locally invasion

- Well-differentiated
  - papillary
  - follicular
- Poorly differentiated (insular)
- Undifferentiated (anaplastic)

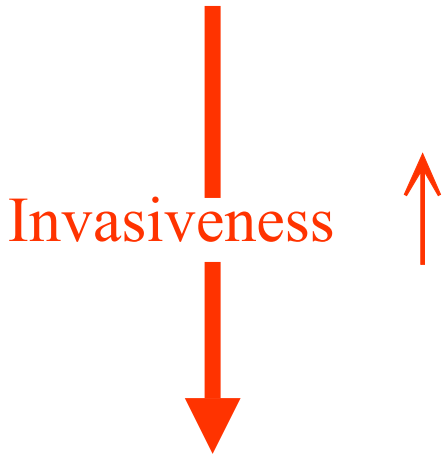

- Medullary
- Others: thyroid lymphoma, squamous cell carcinoma, etc.

Anaplastic carcinoma

Introduction

- 2-10% of all primary thyroid cancer
- Peak incidence: 6th and 7th decade
- One of the most lethal tumour
- ½ of thyroid cancer death
- Decreasing in incidence:
  - refined and accurate diagnosis
  - early resection for differentiated thyroid cancer
  - iodine prophylaxis
  - improvement in socioeconmic status

Anaplastic carcinoma
Clinical features

- History of long-standing goitre
- Rapidly enlarging neck mass
- Pain and compressive symptoms
- Invasion of contiguous structures (70%):
  - trachea, larynx, oesophagus, carotid vessels and skin
  - hoarseness of voice due to RLN palsy
- Cervical nodal metastases (40%)
- Distant metastases (50%)
  - lung, bone, liver, brain and adrenal glands
  - 25% during course of disease

Anaplastic carcinoma

Pathology

- Spindle, polygonal and giant cells
- Epithelial neoplastic structures
- Sarcomatous differentiation components
- Concomitant WDTC: 24-89%
  - WDTC to insular to undifferentiated
  - accumulation of allelic loss
  - dedifferentiation/transformation: <1%

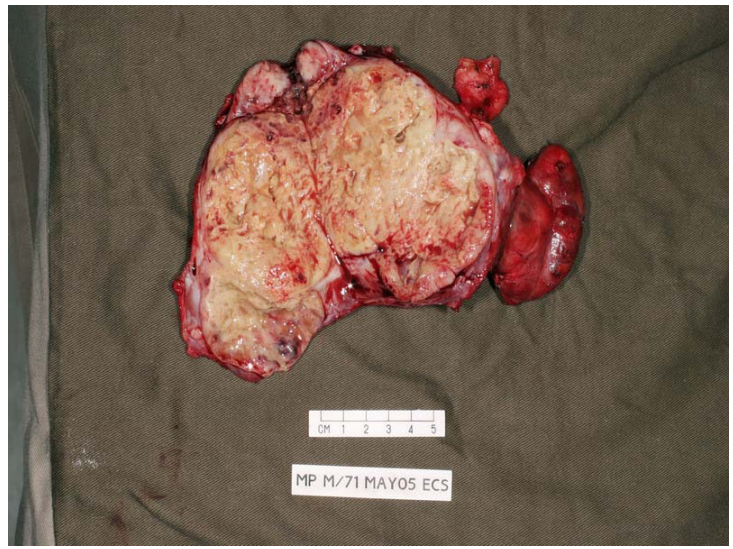

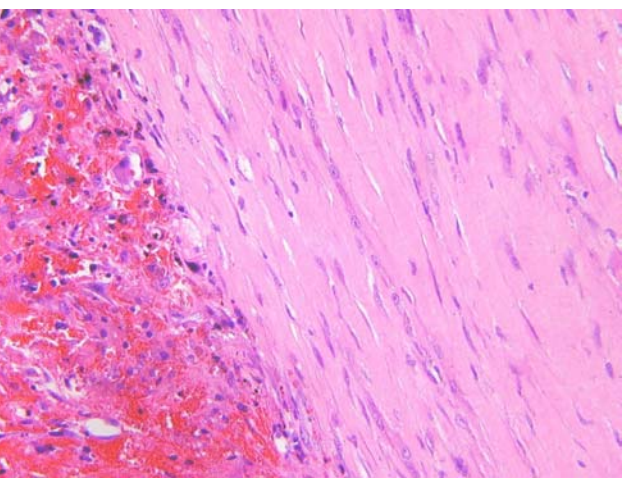

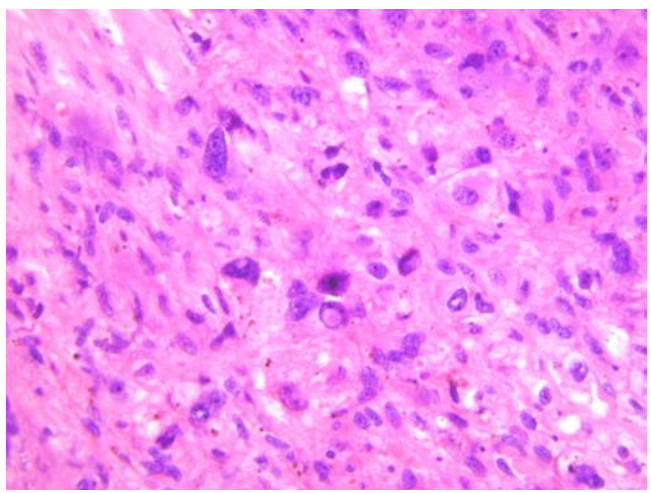

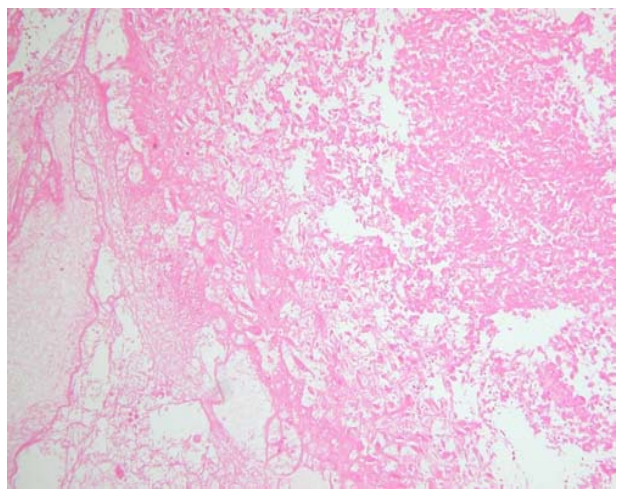

Anaplastic carcinoma

Diagnosis

- Clinical suspicion
- FNAC: immunotyping and markers
- DDx: MTC, insular carcinoma, lymphoma, SCC
- Open/core biopsy
- Biopsy of LN or metastases
- WDTC or recurrence with anaplastic transformation

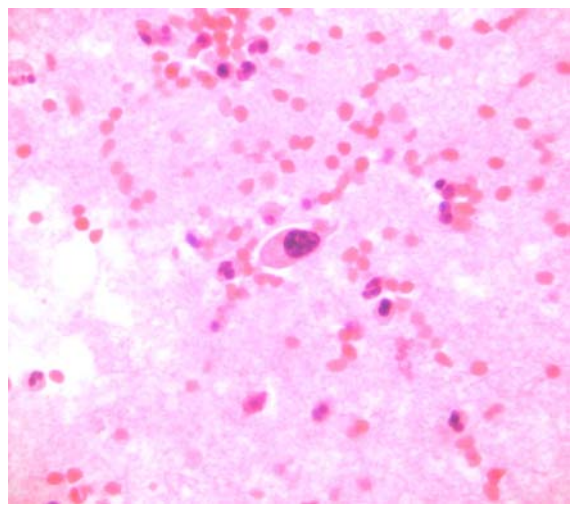

Anaplastic carcinoma

Investigations

- Blood tests
- Laryngoscopy
- CXR
- USG/CT/MRI
- Bone scintigraphy
- PET scan

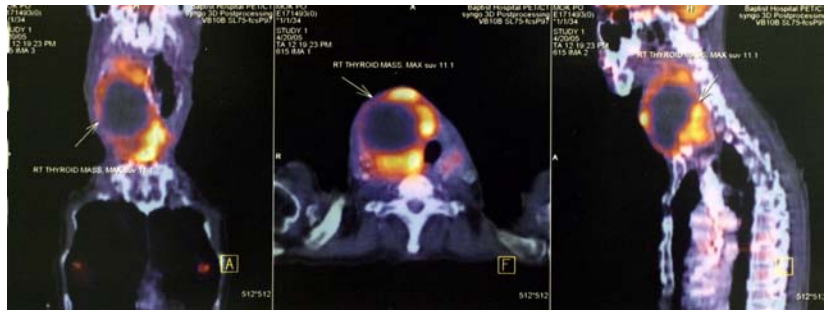

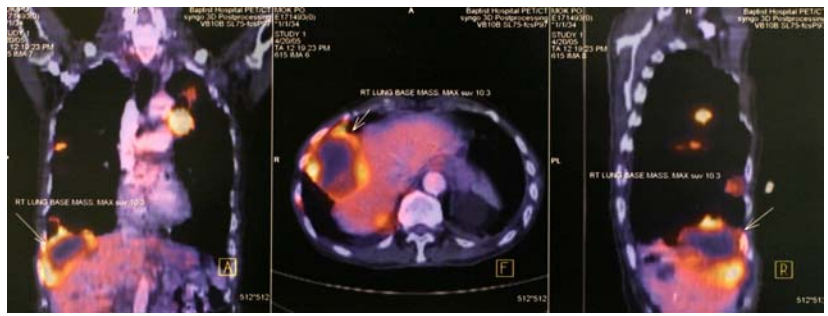

Anaplastic carcinoma

Treatment dilemma

- Surgical emergency
- Delayed presentation
- Advanced disease
- Elderly with poor co-morbid state
- Aggressive and rapidly growing
- Frequent distant metastases
- Lack of effective treatment
- Invariably palliative and fatal

Anaplastic carcinoma

Options

- Surgery
- Chemotherapy
- Radiotherapy
- Combined multimodal therapy
- New targeted therapies

Anaplastic carcinoma
Surgical options

- Resection: complete/debulking
  - for selected patients
  - potential curative
  - facilitate postoperative therapy
  - possibly palliative
  - avoid tracheostomy
  - pre-requisite
    - preserve vital structures
    - without inducing morbidity

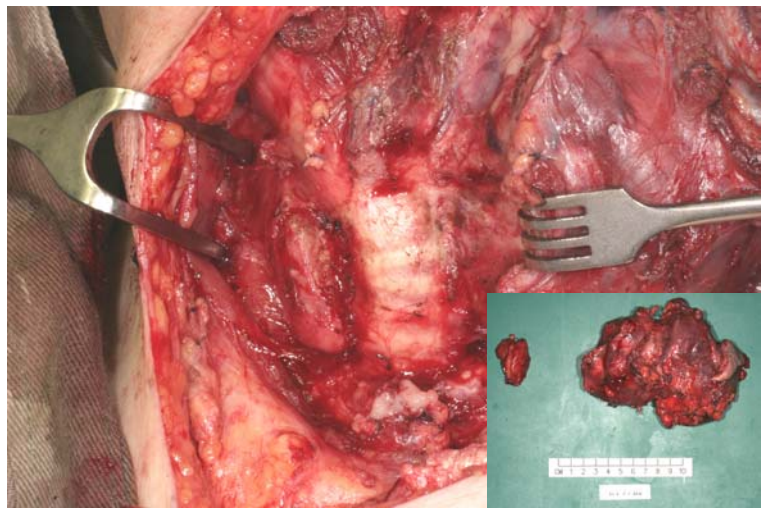

Anaplastic carcinoma

Surgical options

- Radical resection
  - inducing morbidity
  - low chance of cure
  - poor form of palliation

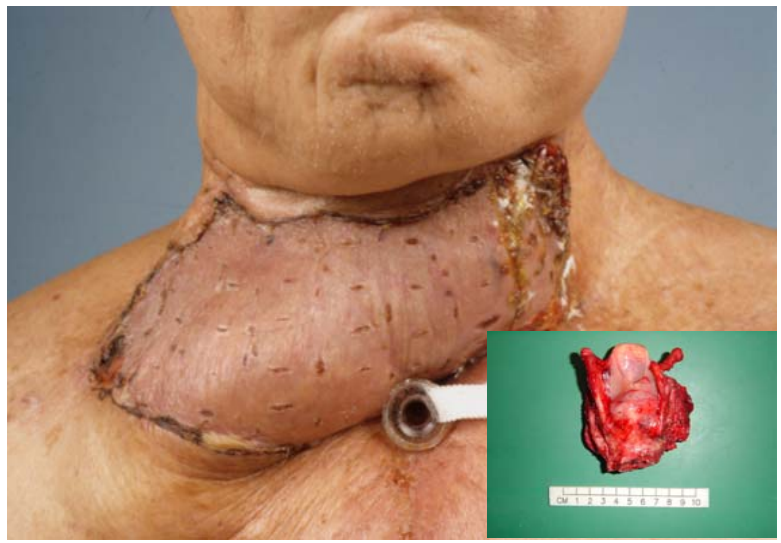

- Tracheostomy
  - palliating airway obstruction
  - not performed prophylactically

Anaplastic carcinoma

Treatment options

- Radiotherapy
  - combined with surgery or chemotherapy
  - postoperative radiation
  - hyperfractionated radiotherapy±chemotherapy
  - surgery for residual disease in responders
  - can be primary treatment option for all patients

- Chemotherapy
  - combined with surgery and radiotherapy
  - doxorubicin as monotherapy
    - poor response rate
    - as radiosensitizer
  - cyclophosphamide, bleomycin, 5-FU
  - taxol or taxotere

Management strategies

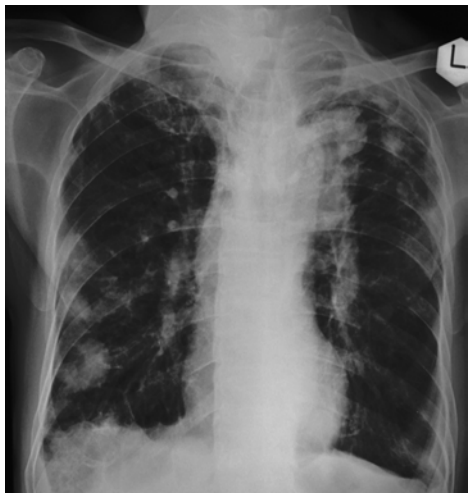

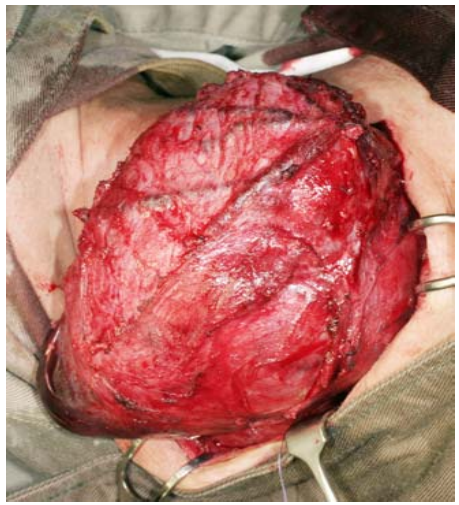

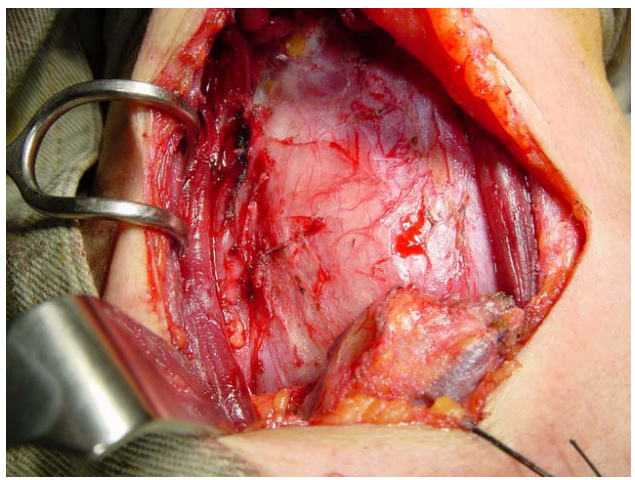

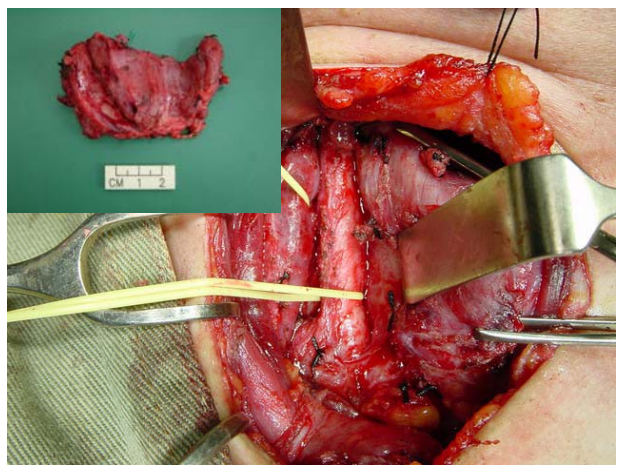

Management strategies

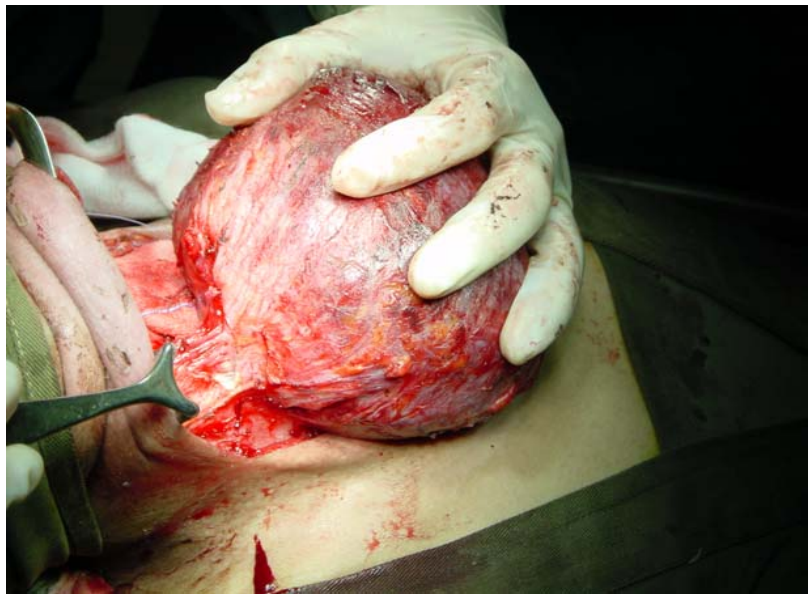

Treatment outcome of anaplastic carcinoma

Author (Yr)	No.	Rx	Median (mean) survival (mths)	1-yr (2-yr) survival (%)
Auersperg (1990)	89	SRC	-	7.9
Venkatesh (1990)	121	SRC	7.2	-
Schlumberger (1991)	20	SRC	6	-
Wong (1991)	32	SRC	6	-
Demeter (1991)	17	SR	12	(29)
Junor (1992)	91	SR	5	(11)
Hadar (1993)	48	SRC	7	(28)
Levendag (1993)	51	SR	7.5	-
Tennvall (1994)	33	RC	4	-
Biganzoli (1995)	11	SC	2	-
Tan (1995)	21	SRC	4.5	10
Kobayashi (1996)	37	SRC	-	8
Nilsson (1998)	81	SRC	(4.3)	(10)
Lo (1999)	28	SR	1.3	(4)
Passler (1999)	120	SRC	3.1	12
Voutilainen (1999)	33	SRC	2.5	9.7

Treatment outcome of anaplastic carcinoma

Author (Yr)	No.	Rx	Median (mean) survival (mths)	1-yr (2-yr) survival (%)
Ain (2000)	19	SRC	6	-
Lam (2000)	38	SRC	2	-
Haigh (2001)	33	SRC	3.8	(20)
McIver (2001)	134	SRC	3	9.7
Besic(2001)	79	SRC	6	25
Sugitani (2001)	47	SRC	(6)	16
Pierie (2002)	67	SRC	51	35
Tennvall (2002	32	SRC	4.5	16
Sugino (2002)	29	SRC	-	41
De Crevoisier (2004)	30	SRC	10	46
Kihara (2004)	19	SRC	9.4	21
Veness (2004)	18	SRC	6.2	
Kebebew (2005)	516	SR	3	19.3
Goutsouliak (2005)	75	SRC	5.1	19
Besic (2005)	188	SRC	3	13

Anaplastic carcinoma
Novel therapies

- Target therapy:
  - EGFR and VEGF inhibitors
  - sodium iodide symporter re-differentiation therapy
  - bovine seminal ribonuclease
  - vascular targeting therapy: combretastatin A4
  - Gene therapy:p53 and others (bcl-2, cyclin D1, ß-catenin, Met, c-myc, Nm23 and ras)
  - combined with chemotherapy

- Evidence:
  - inhibit cellular proliferation and induce apotosis in cell lines
  - control tumour growth in nude mice xenograft

Anaplastic thyroid carcinoma

Summary

- Anaplastic thyroid carcinoma commonly presents as locally advanced disease associated with distant metastases in elderly patients
- It is an invariably lethal disease associated with dismal prognosis because of the lack of effective therapies
- Treatment aims at effective palliation in particular to airway obstruction
- The development of new target therapies is essential and promising

Locally advanced thyroid carcinoma

Well-differentiated thyroid carcinoma (WDTC)

- an adequate resection feasible
- potentially cure after radical resection
- availability of adjuvant therapies
- associated with long-term survival

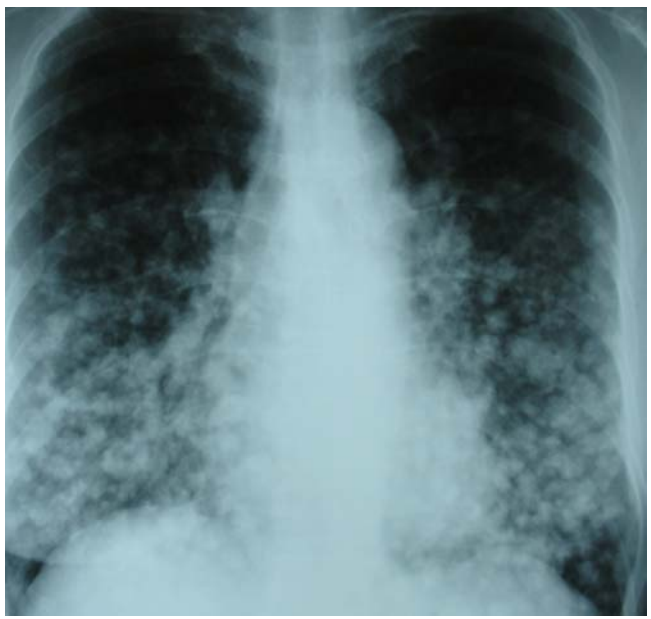

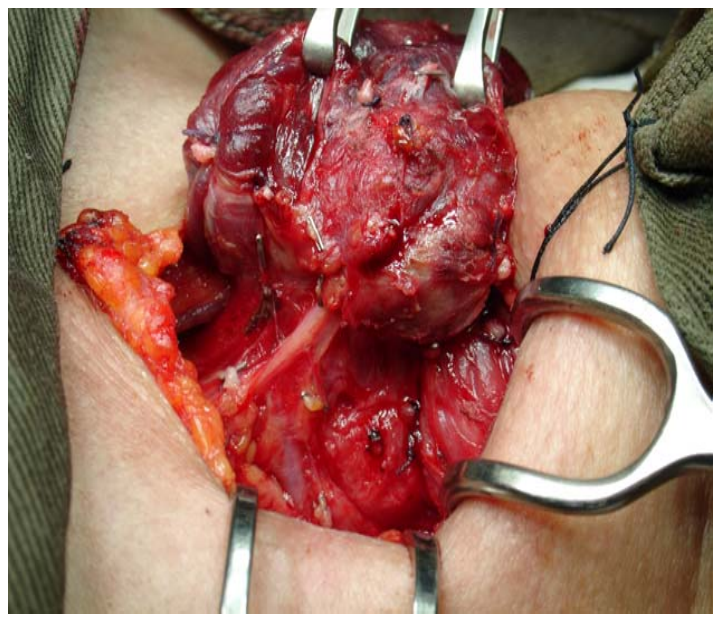

Well differentiated thyroid carcinoma

Treatment and controversies

- Primary treatment
  - thyroidectomy
    - extent and radicality
  - neck dissection for nodal metastases
    - nature and type

- Adjuvant therapies
  - administration of I^{131} ablation
  - indication of external radiation therapy
  - need of T_4 suppressive therapy

Well differentiated thyroid carcinoma

Summary of treatment and outcome

- 80%: do well with lobectomy or more aggressive treatment
- 5%: do poorly despite aggressive treatment
- 15%: benefit from total thyroidectomy/aggressive resection followed by I^{131} ablation and TSH suppressive therapy

	Low risk	High risk
% of patients	85-90	10-15
Mortality (10-20 yrs)	2-5 %	40-50 %
Recurrence rate	10 %	45 %

Well differentiated thyroid carcinoma

Risk group stratification

- AGES (**A**ge, **G**rade, **E**xtent, **S**ize)
- AMES (**A**ge, distant **M**etastasis, **E**xtrathyroidal Invasion, **S**ize)
- Degroot (Intrathyroidal, Lymph nodes, Extrathyroidal invasion, Metastasis)
- UICC/AJCC pTNM classification
- MACIS (Distant **M**etastasis, **A**ge, **C**ompleteness of resection, **I**nvasiveness, **S**ize)

Locally advanced WDTC
Management and considerations

- High-risk patients
  - invasion/pT4/extrathyroidal extension
  - incomplete resection

- Management
  - extent of surgical resection
    - total thyroidectomy
    - complete/radical resection
  - postoperative adjuvant therapies
    - I^{131}: improve survival and decrease recurrence
    - external RT: facilitate locoregional control

Locally advanced WDTC

Value of external beam irradiation (EBRT)

- High-risk disease: pathological stage pT4 or N1

Authors (year)	Local recurrence rate at 10-yr (%)	
	Surgery±I^{131}	Surgery+EBR±I^{131}
Ford (2003)	63	18
Tubiana (1985)	21	14
Simpson (1988)	18	14
Esik (1994)	52	11
Tsang (1998)	22	7
Kim (2003)	38	5
Phlips (1993)	21	3
Farahati (1996)	50	1

Locally advanced WDTC

Types of adjacent structures invasion

- strap muscles
- perithyroidal soft-tissue
- recurrent laryngeal nerve
- upper aerodigestive tract
  - trachea
  - larynx
  - oesophagus
- vascular structures
- bony structures: manubrium

Locally advanced/invasive WDTC

Definition and incidence

- Extrathyroidal extension ≠ pT4 tumours
- Subclassification (2002 TNM 6th Edition):
  - pT3: sternohyoid muscle, perithyroid tissue
  - pT4a: larynx, tracheal, oesophagus, recurrent nerve
  - pT4b: prevertebral fascia, mediastinal/carotid vessels
- Significance of aerodigestive tract invasion:
  - up to 20% overall incidence
  - up to 50% disease-related death
    - asphyxia
    - hemoptysis

Locally advanced/invasive WDTC

Therapeutic challenge and controversy

- Surgical options:
  - radical resection (pT3 and pT4a)
  - conservative shaving procedure
    - residual microscopic tumour (pT4a)
    - gross residual tumour (pT4a and pT4b)

- Outcome considerations:
  - oncological principle
  - functional preservation
  - medical evaluation/physical conditions
  - availability of adjuvant therapy

WDTC with trachea invasion
Shaving procedure

- 28 of 47 patients with larynx or trachea invasion
- Curative resections
- Without laryngectomy or tracheal resection
- Outcome:
  - 10-yr overall survival rate: 62%
  - 10-yr disease-free survival rate: 50%
- Recommendation:
  - surgical removal of all gross disease
  - preservation of function if possible

Breaux EP Jr, et al. Am J Surg 1980

WDTC with trachea invasion

Shaving procedure

- 1979-1988:
  - 16 of 432 patients
  - 14 PTC and 2 FTC
- Treatment:
  - cartilage-shaving with gross tumour removal
  - postoperative I^{131} (n=11) and/or EBR (n=5)
- Mean follow-up: 70.7 (36-122) months
  - 7 died (22-82 months)
  - 5 persistent/recurrent disease (43-122 months)
  - 4 disease free (49-112 months)
- Recommended for more extensive resection

Park CS, et al Head Neck 1993

Locally advanced PTC

Types of invasion and resection

- 1940-1990: n=262
- Extrathyroidal invasion
- 63% 10-yr overall survival
  - Types of invasion
  - Type of resection
    - I: complete resection
    - II: shave resection
    - III : gross tumour left

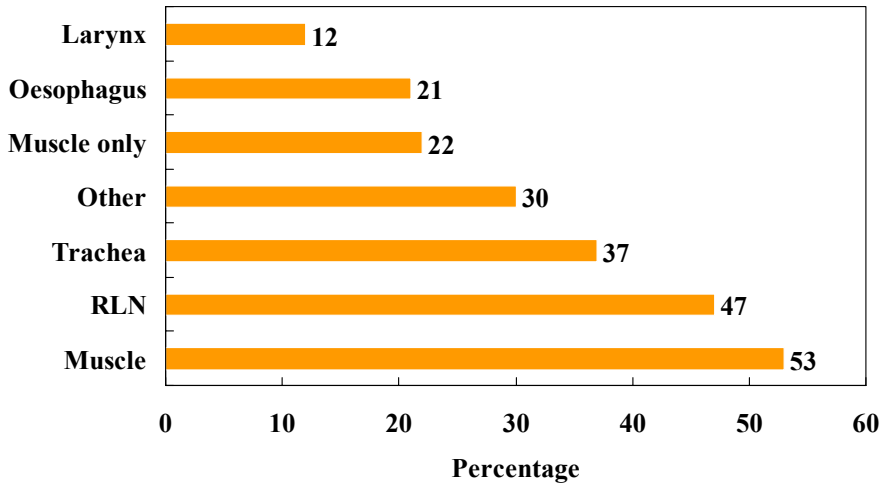

Factor	Beta	SE	t	p
Trachea	0.38	0.19	2.00	<.05
Oesophagus	0.34	0.20	1.74	<.05
Incomplete resection	0.14	0.10	1.42	.07

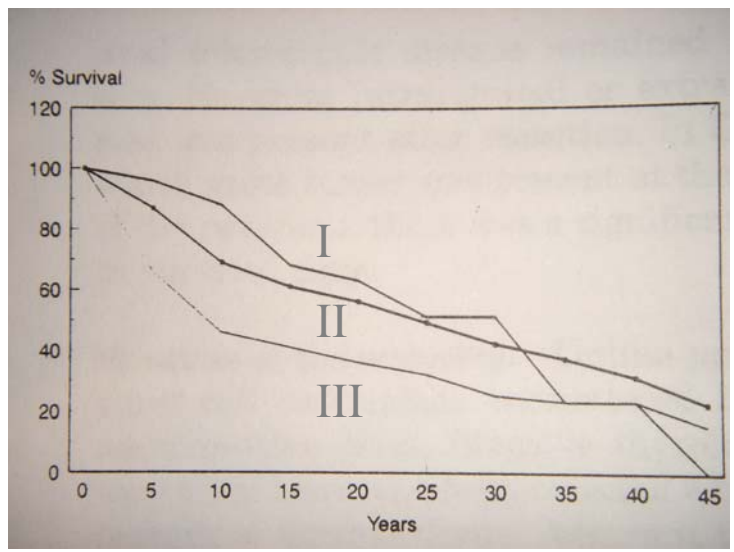

McCaffrey TV, et al Head Neck 1994

Different surgical strategies

Long-term survival

Author(yr)	S (No.)	C (No.)	In (No.)	Mean FU (yr)	S Vs C	C Vs In	S Vs In
Bayles(1988)	-	2	10	3.75	-	+ve	-
Czaja(1997)	75	34	15	-	ND	+ve*	+ve*
Friedman(1994)	18	14	2	5	-ve	+ve	+ve
Ishihara(1991)	-	34	26	-	-	+ve	-
Lipton(1987)	20	14	14	8	ND	+ve*	+ve*
McCaffrey(1994)	-	-	-	13	ND	+ve*	+ve*
Melliere(1993)	20	6	19	6.25	ND	+ve	+ve
Segal(1984)	15	13	-	-	ND	-	-

S=shaving; C=complete resection; In=incomplete resection; *=statistically significant
+ve: better survival; -ve: worse survival; ND: no difference; -: not available

WDTC with invasion of larynx and trachea

Staging system

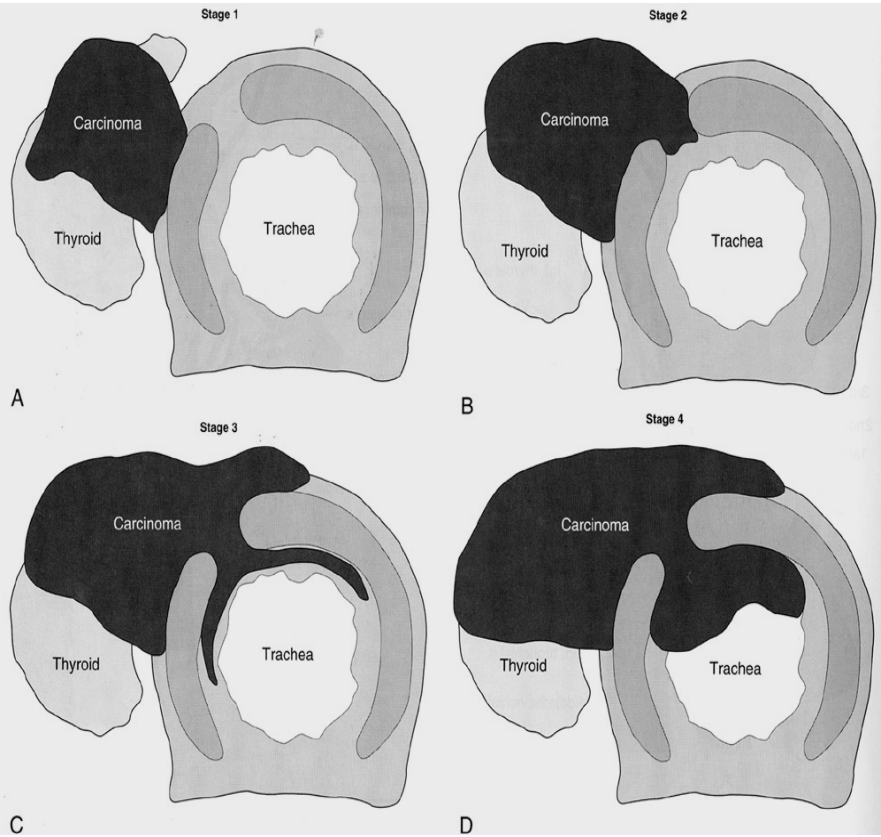

Stage	Description
I	Extends through the capsule of the thyroid gland and abuts the external perichondrium
II	Invades between the rings of cartilage or destroys cartilage
III	Extends through the cartilage or between the cartilaginous plates into the lamina propria of the tracheal mucosa
IV	Extends through the entire thickness of, and expands the trachea mucosa, and is visible through a bronchoscope

Shin MH et al Hum Pathol 1993

WDTC with aerodigestive tract invasion

Types of resection and reconstruction

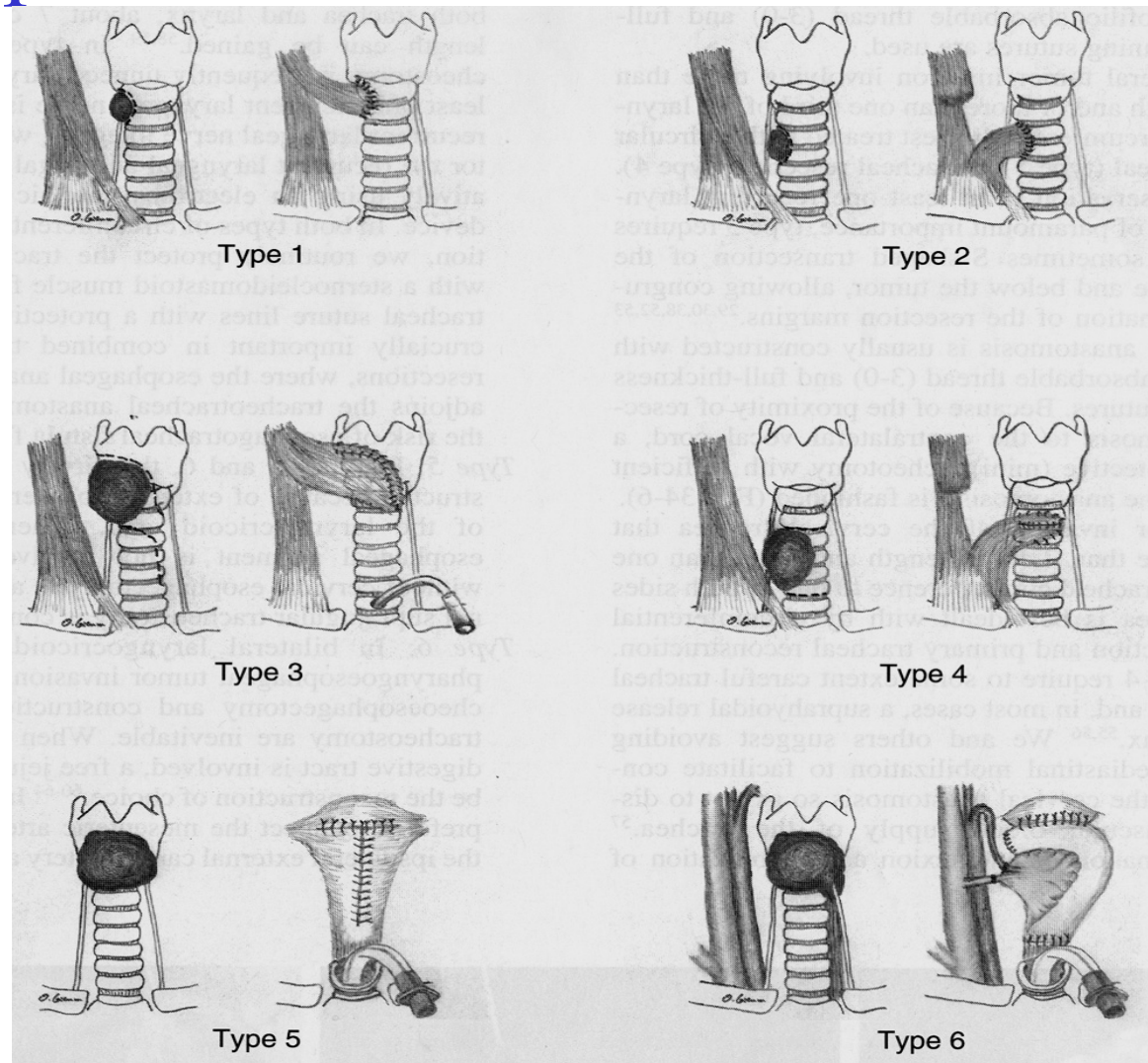

Dralle H, In: Clark OH (eds) Textbook of Endocrine Surgery. Elsevier 2005

WDTC with aerodigestive tract invasion

Frequency of resection types

Author (yr)	No.	Types of resection				Mortality
		Laryngectomy	LTE	Window	Circumferential	
Ishihara (1991)	60				60	1
Grillo (1992)	34		7	1	26	2
Friedman (1992)	13			13		0
Dralle (1993)	24		6	18		2
Ozaki (1995)	21				21	0
Azakura (1997)	3			3		0
Bayles (1998)	14	4	5	2	3	0
Mulsholt (1999)	17			6	11	2
Kim (2000)	16	6		2	8	0
Yang (2000)	8				8	0
Machens (2001)	15	2	2	6	5	0
Nakao (2001)	31				31	0
Dralle (2004)	28	5	4	10	9	2
Total	**284**	**17 (6%)**	**24 (8%)**	**61 (22%)**	**182 (64%)**	**9 (3.2%)**

Surgical strategies

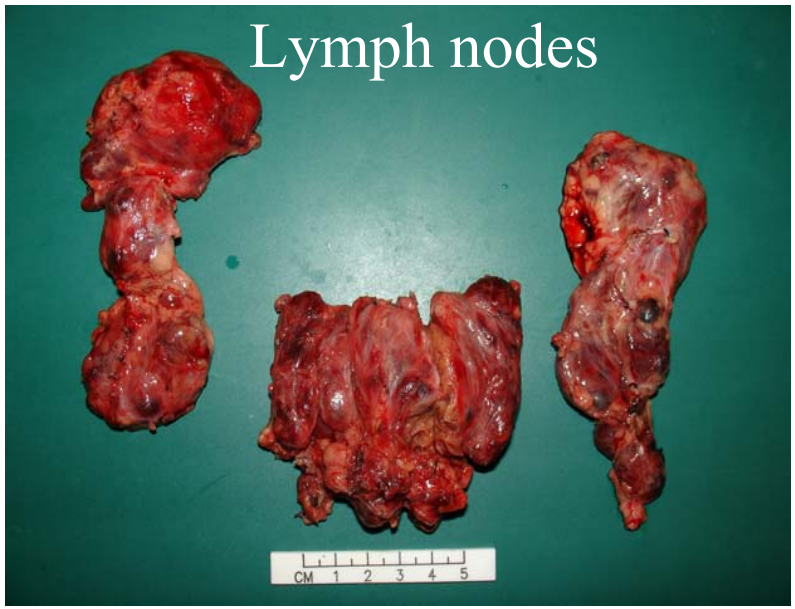

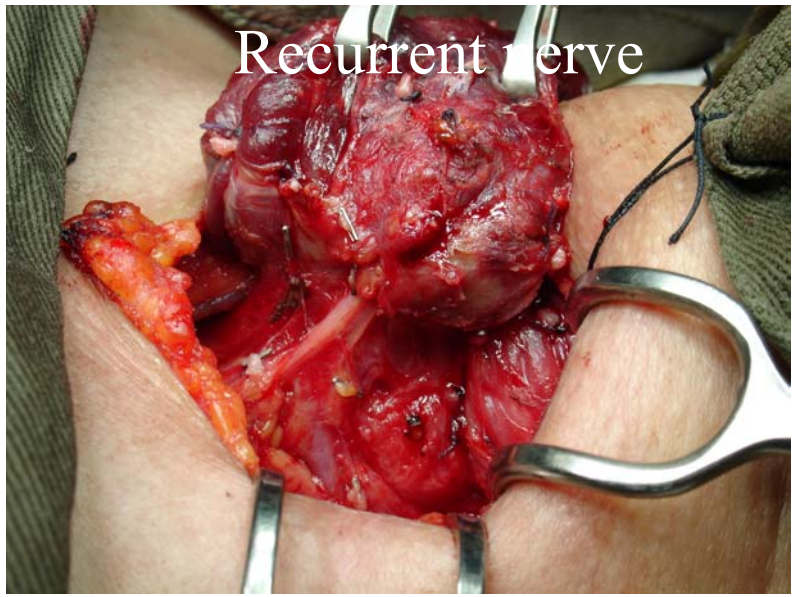

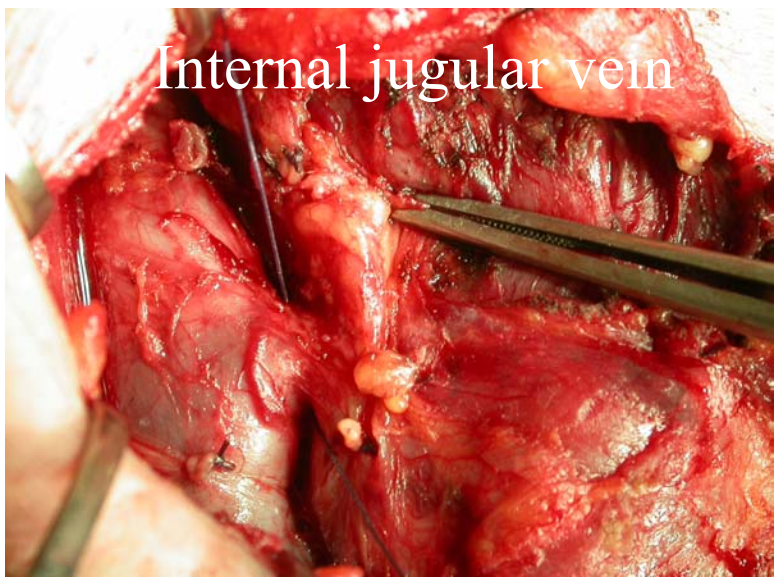

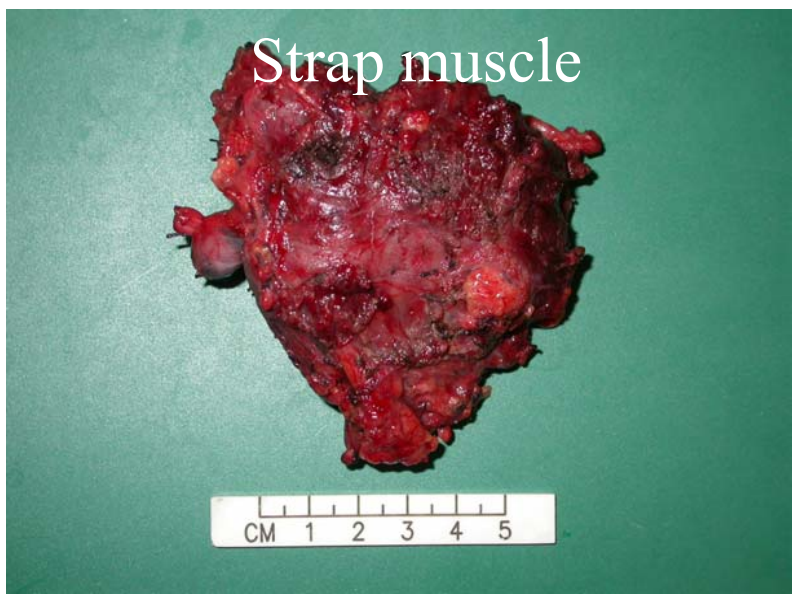

Surgical strategies

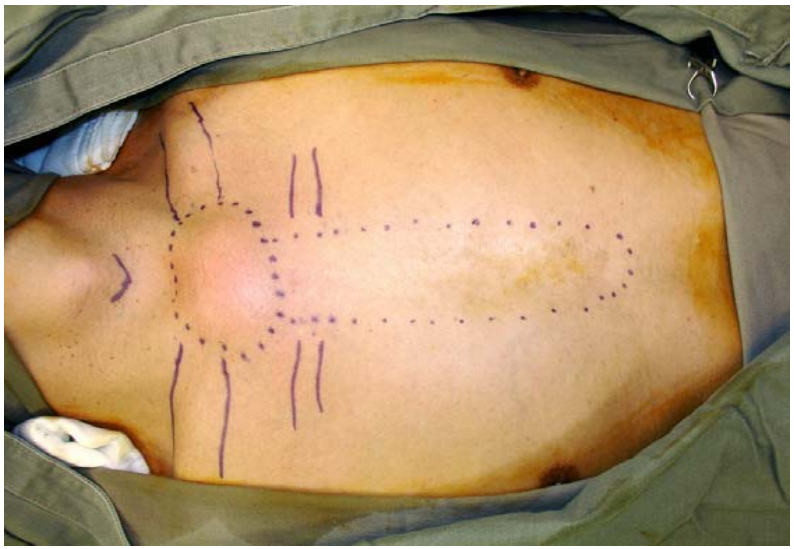

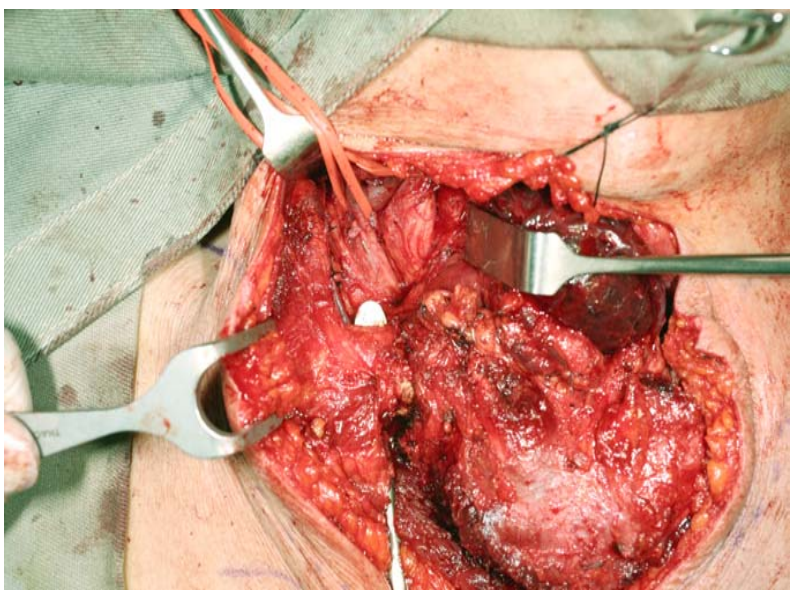

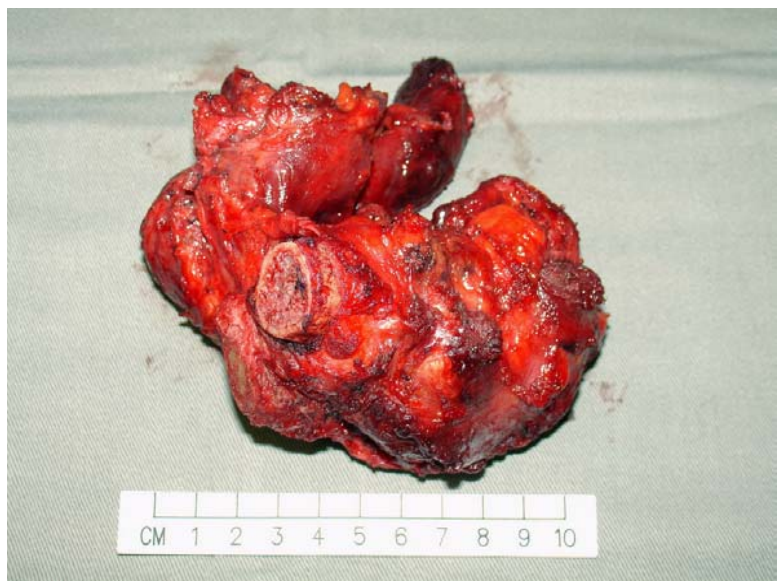

Shaving resection

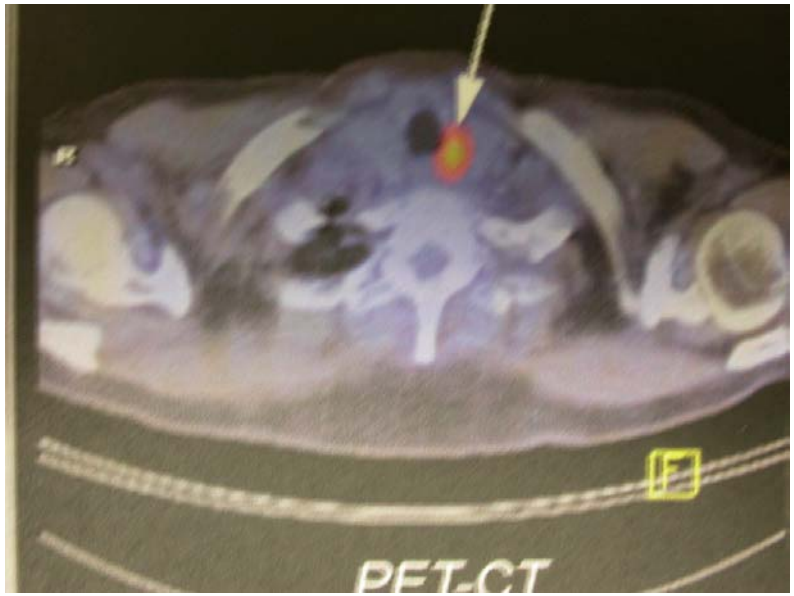

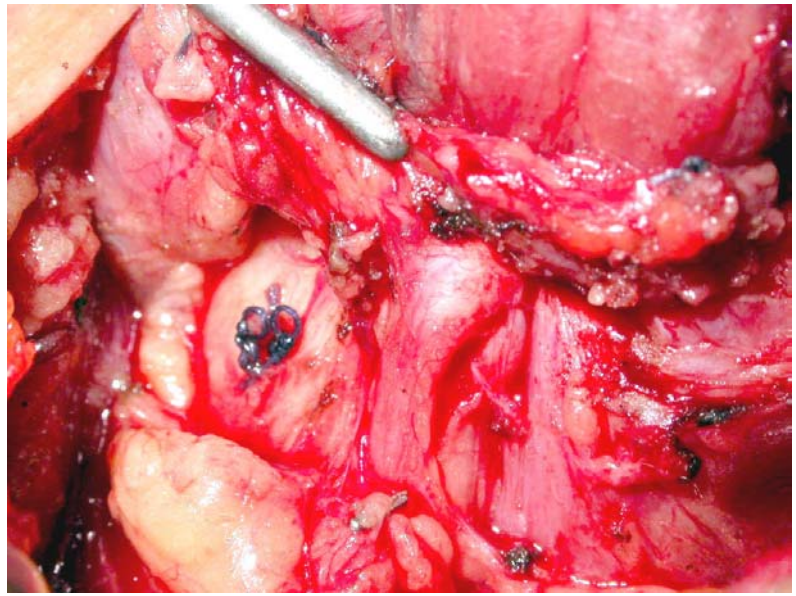

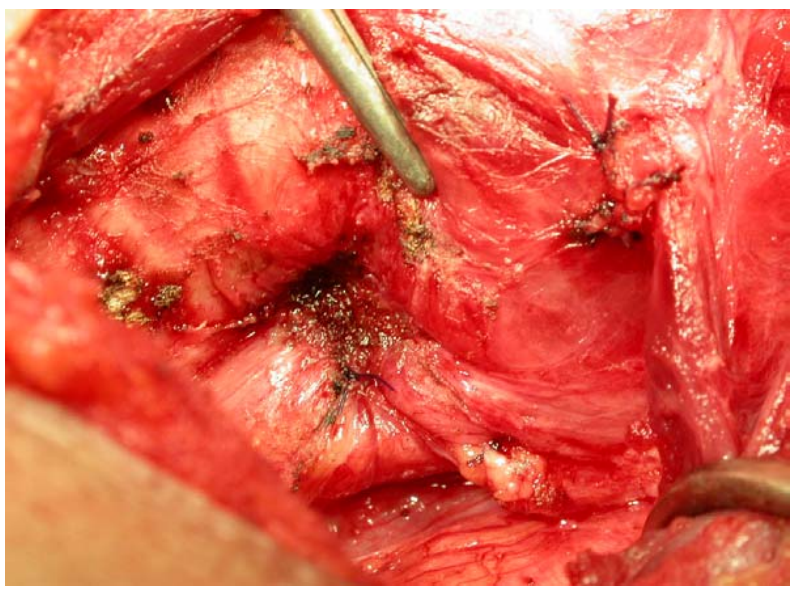

Circumferential tracheal resection

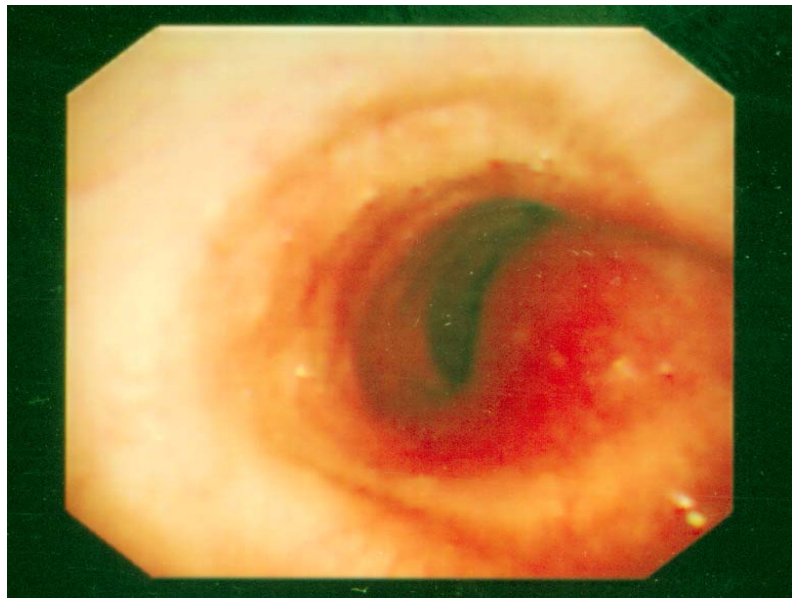

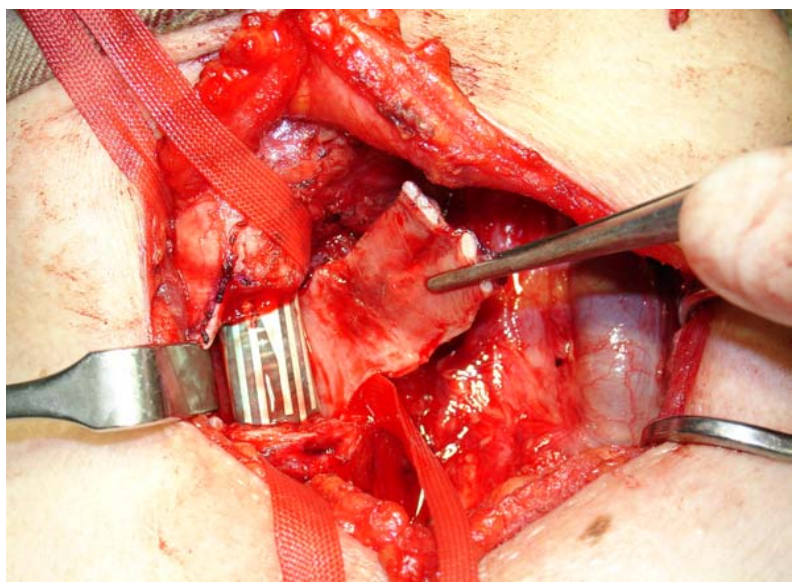

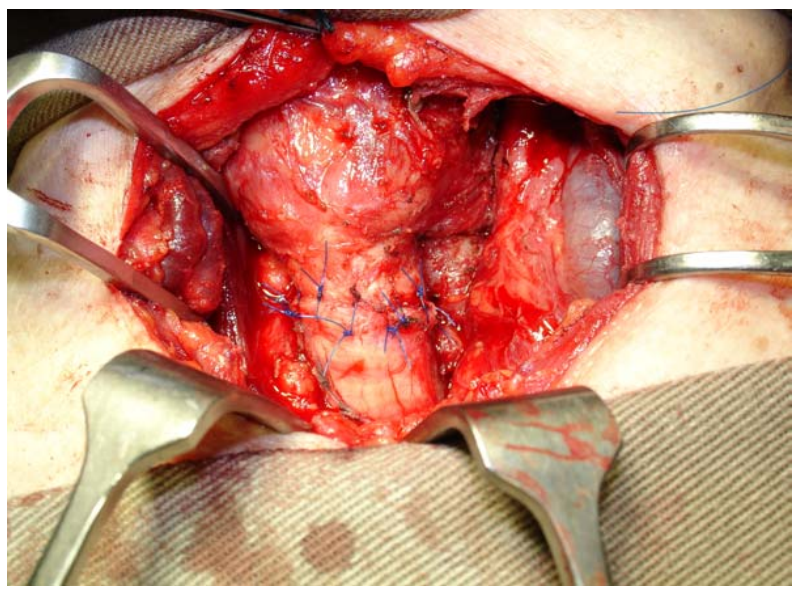

Preservation of recurrent laryngeal nerve

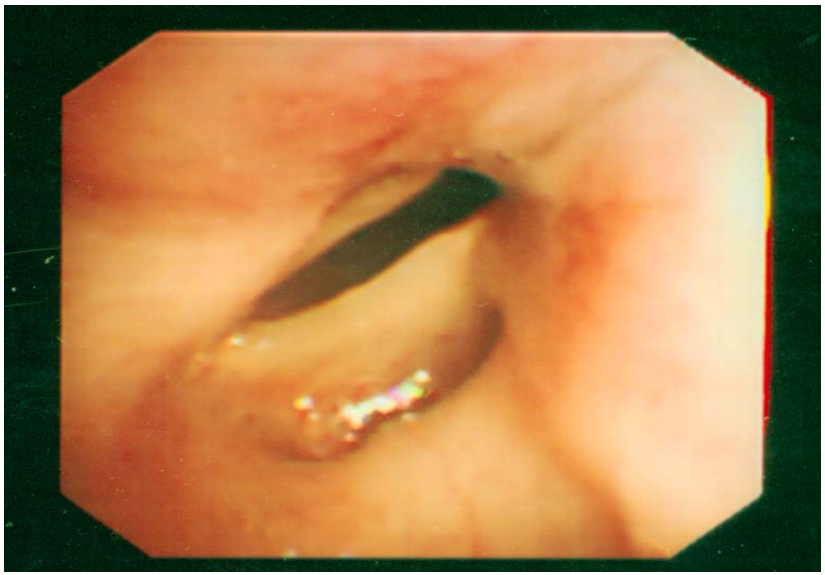

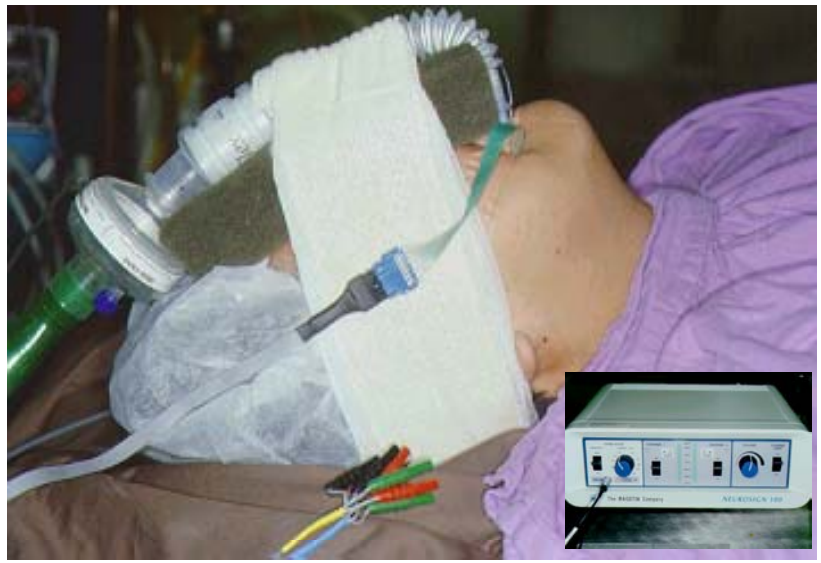

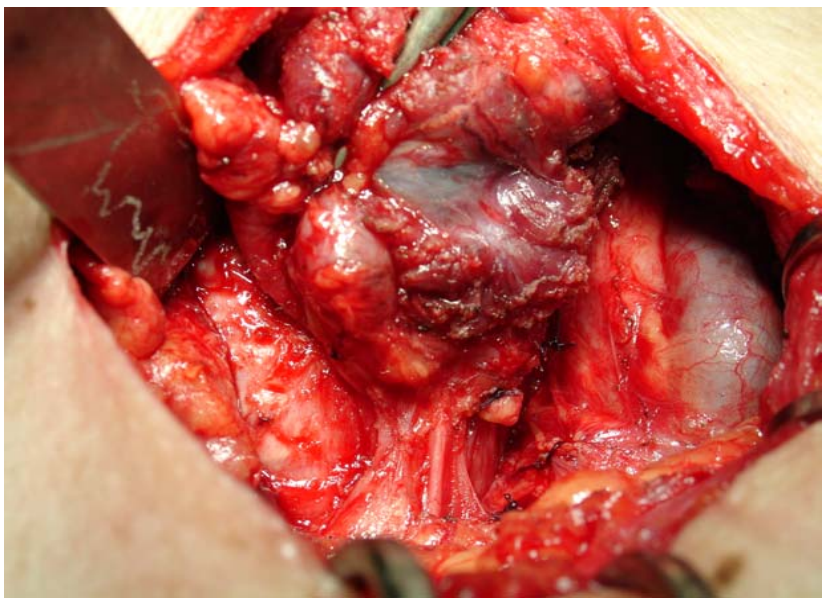

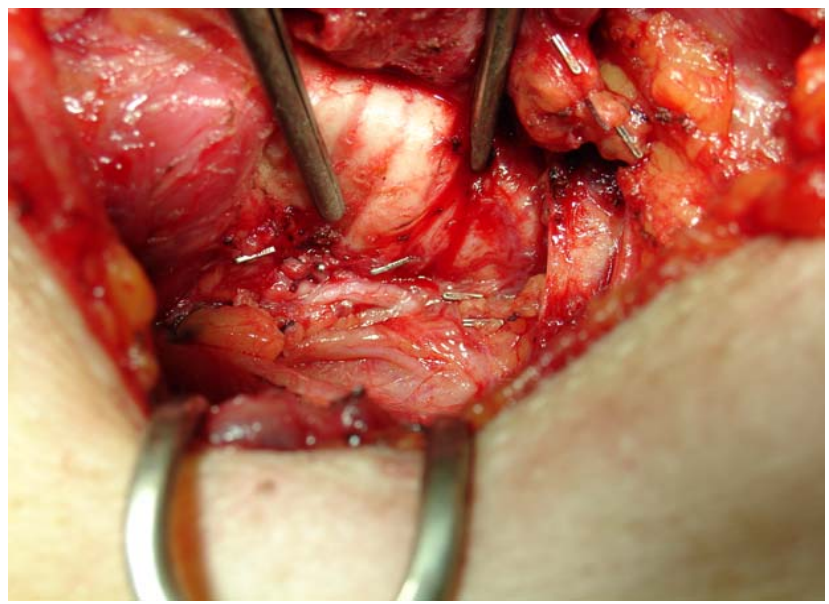

Laryngotracheal resection

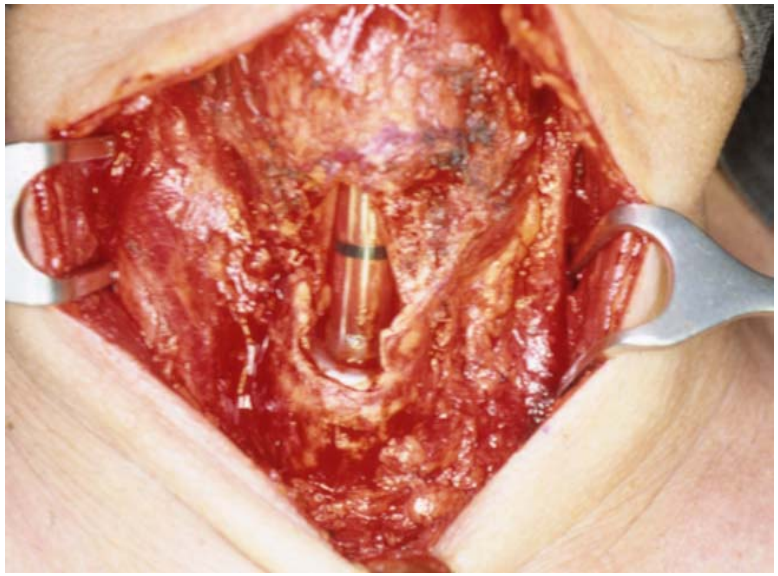

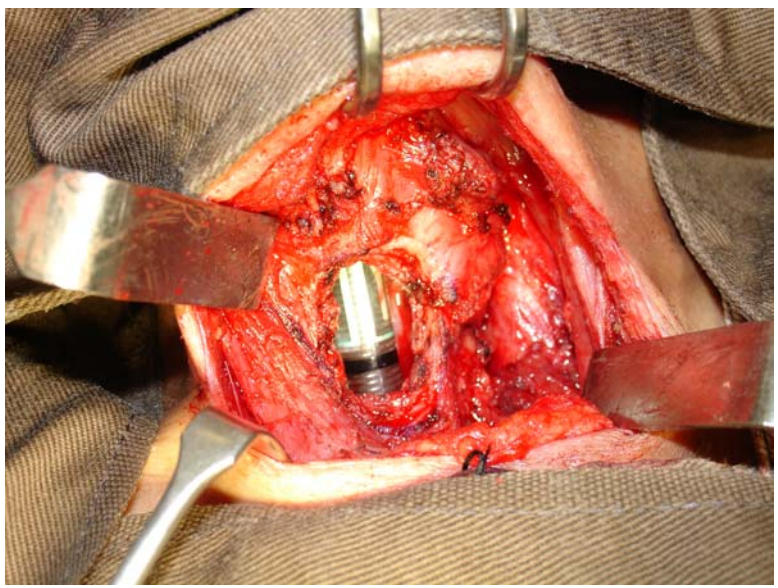

Locally advanced WDTC

Summary (1)

- Management of locally advanced WDTC depends on the extent and site of invasion
- Complete resection should be attempted without inducing significant morbidity
- Shaving with possibly incomplete resection should be considered for functional preservation aiming at macroscopic clearance

Locally advanced WDTC

Summary (2)

- Laryngotracheal resection and reconstruction is indicated for selected patients to achieve macroscopic clearance
- Postoperative therapies are effective in improving survival and controlling local recurrence for patients with incomplete excision
- Surgical decision should be individualized because of the variable tumour behaviour, functional disability of radical resection and the availability of postoperative adjuvant therapies