


Thyroid Ultrasound for the Endocrine Surgeon: A Valuable Clinical Tool that Enhances Diagnostic and Therapeutic Outcomes

Allan Siperstein MD



The Cleveland Clinic

Audience Quiz

- Taken ultrasound course
- Perform office-based ultrasound of the thyroid/parathyroid
- Are performing FNA +/- sono guidance
- Are performing FNA under sono guidance
- Would like to learn ultrasound
- Have an overwhelming sense of fear and insecurity when someone points to a gray and fuzzy ultrasound image and says “see the thyroid nodule?”

Thyroid

Greek word *thyreos*- shield shaped



Thyroid FNA






Ultrasound in Surgical Practice

- **Ultrasound (U/S) 1st used in medical practice in 1940**
- **Technology evolution**
 - A-mode**
 - B-mode**
 - high resolution gray-scale/Doppler**
- **Surgeon-performed U/S for trauma (1993)**
- **“Working knowledge of head & neck, breast, abdomen, and endorectal U/S”**
 - mission statement of ACS (1996)**



Ultrasound for the Endocrine Surgeon



Neck Ultrasound Endorsed by National Organizations of Endocrinologists

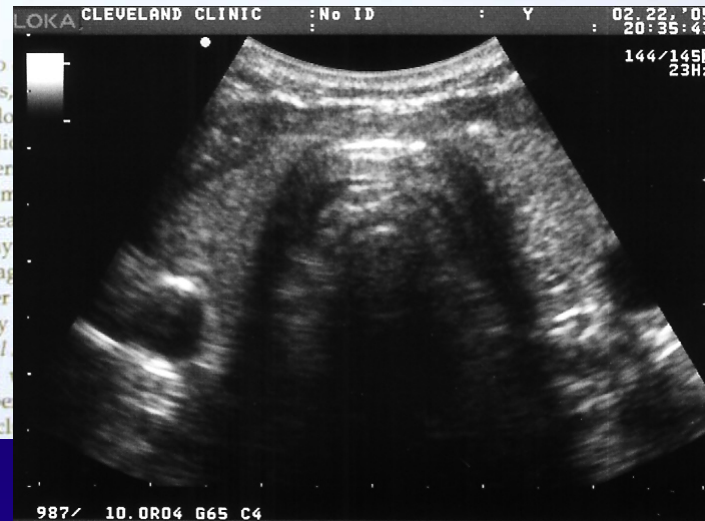THYROID
Volume 14, Number 2, 2004
© Mary Ann Liebert, Inc.

Guest Editorial

Thyroid Ultrasound—Just Do It

H. Jack Baskin

REAL-TIME ULTRASOUND is available for 25 years, derutilized by endocrinologists partly because of the radiation and their lack of understanding and their lack of understanding of its use. It can be useful in the clinical management of thyroid and parathyroid disease. The general attitude among many endocrinologists has been that it had limited ability in diagnosis. This perception was reinforced by the 1982 *Annals of Internal Medicine* article on ultrasound-guided aspiration (FNA) biopsy. This led to the false conclusion



is for defining the...
ent with a neck mass...
trasound quickly and...
in. Indeed, its use as...
s sorrowfully under...
-year medical student...
ocrine fellow after 2...
ultrasound followed...
ysical examination of...
us to teaching exam-...
pe.
exceeded by its use...
ultrasound guidance...
nique. Numerous in-...
nd-guided FNA de-...
from 15-20%



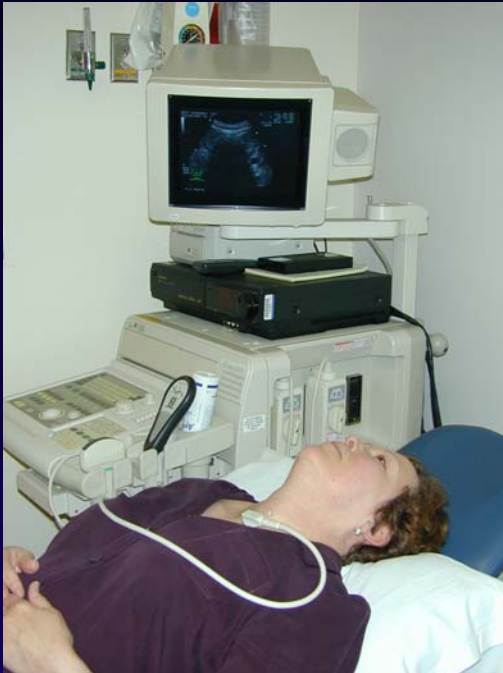Methods

- **Chart and endocrine database review 1999-2004
at The Cleveland Clinic**
- **Routine U/S in the outpatient clinic setting**
- **Clinical outcomes:**
 - Coexisting thyroid/parathyroid disease**
 - Localization of abnormal parathyroids**
 - Thyroid cancer**
 - Resident/fellow education**



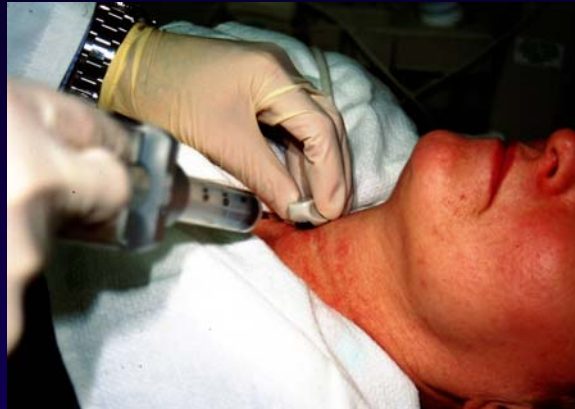Ultrasound for the Endocrine Surgeon

Methods



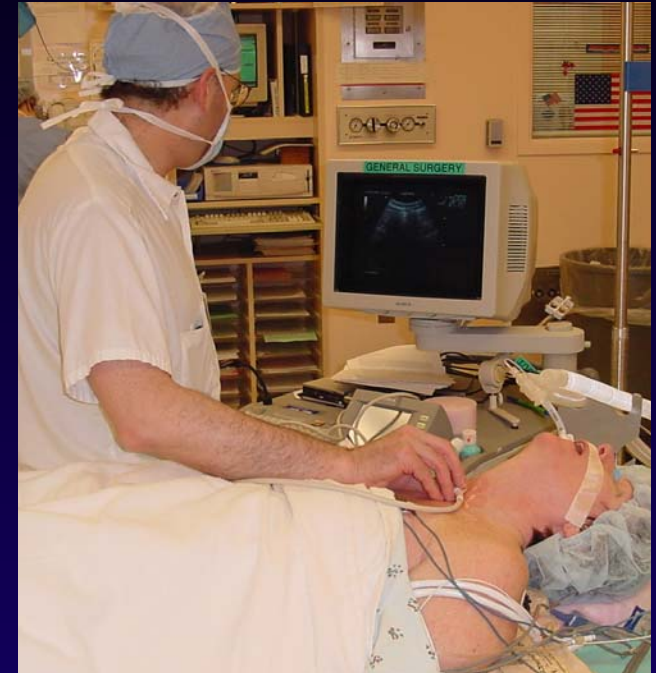Clinic

6-13 MHz
Curvilinear
small parts
transducer



FNA

23 ga needle
>1 cm nodules
atypical morphology
lymphadenopathy



OR

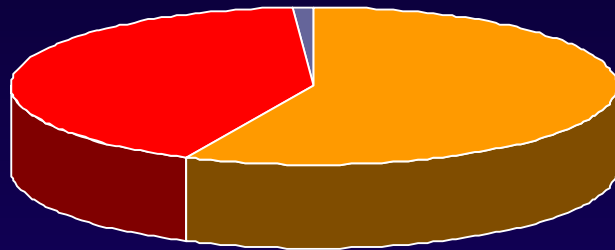
Pre-operative
Intra-operative



Results

5,703 U/S


from Nov 1999 - Nov 2004



■ Parathyroid 57%


■ Thyroid 42%

■ Adrenal 1%



■ Pre-op evaluation 68%

■ Diagnosis/ Follow-up 42%

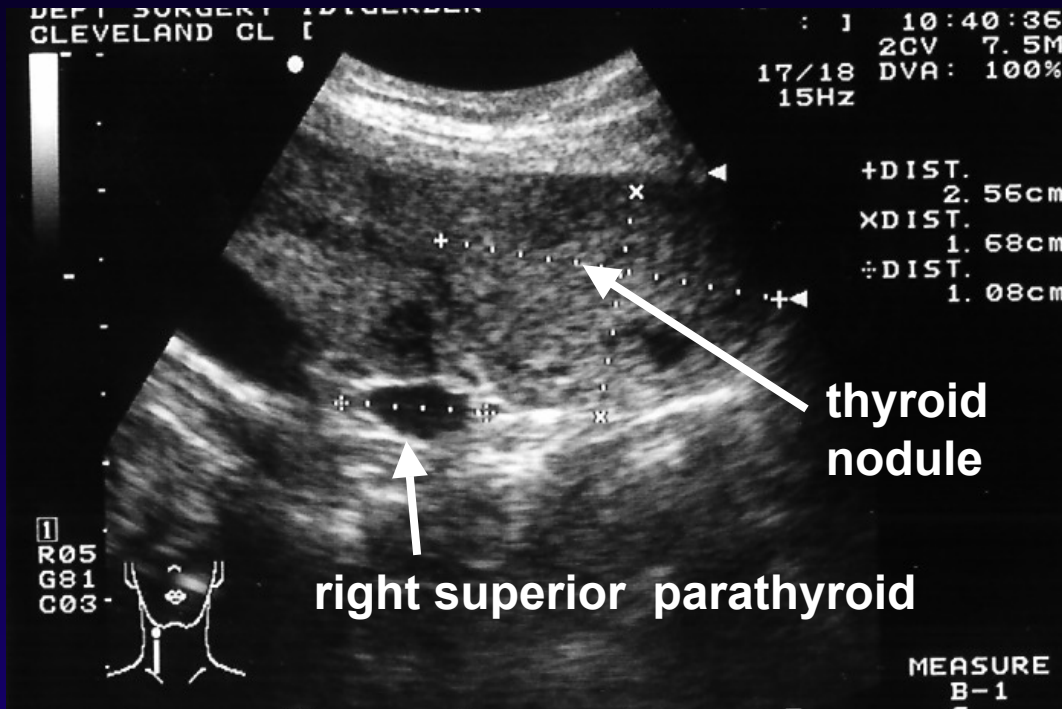


581 FNA biopsies (10%)

<7% inadequate sampling



Results: Coexisting thyroid /parathyroid disease



43% thyroid disease
in patients with HPT

<5% incidental HPT
in patients with
thyroid disease

42% of parathyroid abnormalities
contralateral to side of thyroid
nodule or lobectomy

33% non-palpable
thyroid nodules



Results: Coexisting thyroid /parathyroid disease

350 patients 1° HPT (1999-2003)

↓
150 (43%) abnormal thyroid U/S

↓
70 (20%) thyroid FNA

↙
59 (17%) benign
1.86±0.95 cm

↘
11 (3%) abnormal
2.4±1.3 cm*

↓
10±1 mo
follow-up
(2 wk-47 mo)

9% history
11% XRT
2% prior surgery

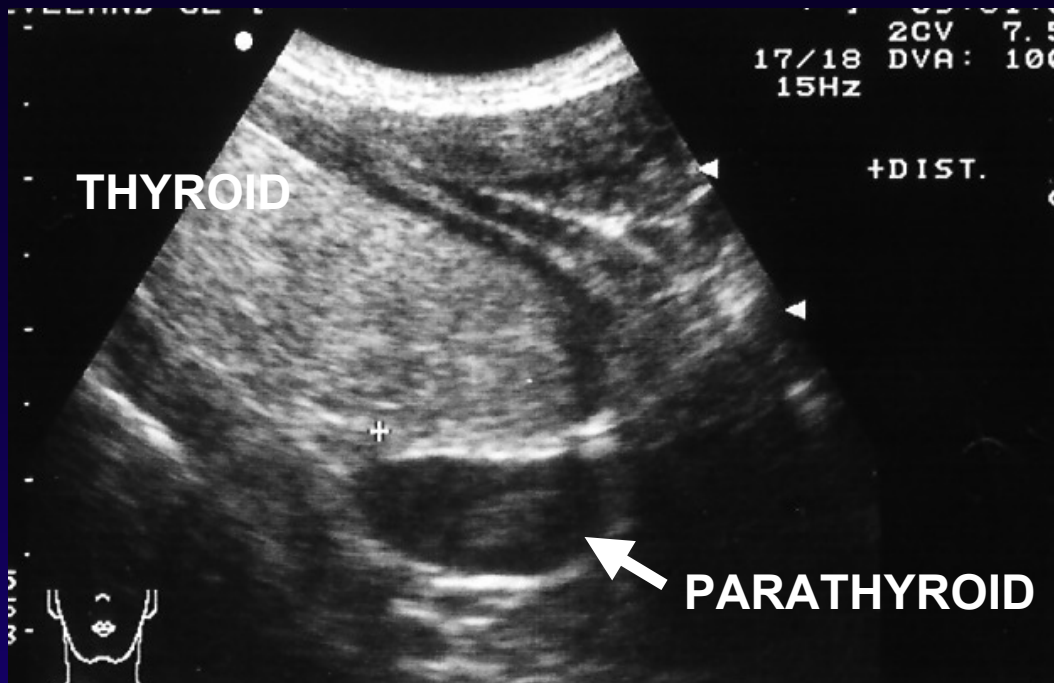
2 XRT
8 large goiters

21 (6%) thyroid surgery

*p=0.17



Results: Localization of Hyperparathyroidism



**Overall accuracy of U/S
in patients with negative mibi
79%**

(⁹⁹Tc-Sestamibi scan 27-68%)

14/350 (4%)
negative ⁹⁹Tc-
Sestamibi scan



12/14 (86%)
single abnormal
parathyroid on U/S

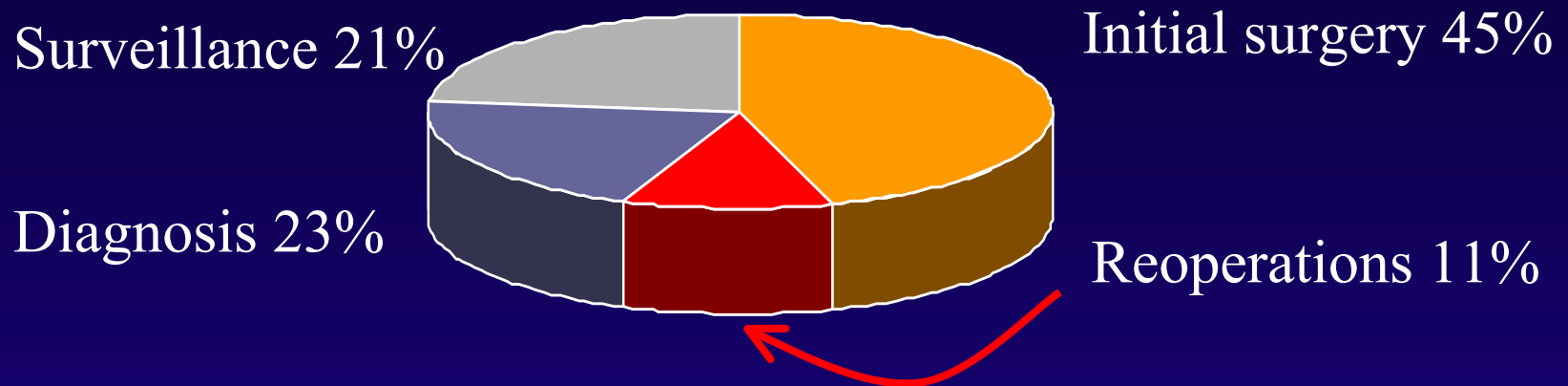


9/12 single adenoma
3/12 double adenoma/
hyperplasia/other site



Results: Thyroid Cancer Diagnosis, Surgery
& Surveillance

Clinic U/S in 141 patients with thyroid cancer



Neck U/S modified therapy in nearly $2/3$ patients



Ultrasound for the Endocrine Surgeon

Results: Thyroid Cancer Diagnosis, Surgery & Surveillance

Neck U/S modified therapy in nearly 2/3 patients

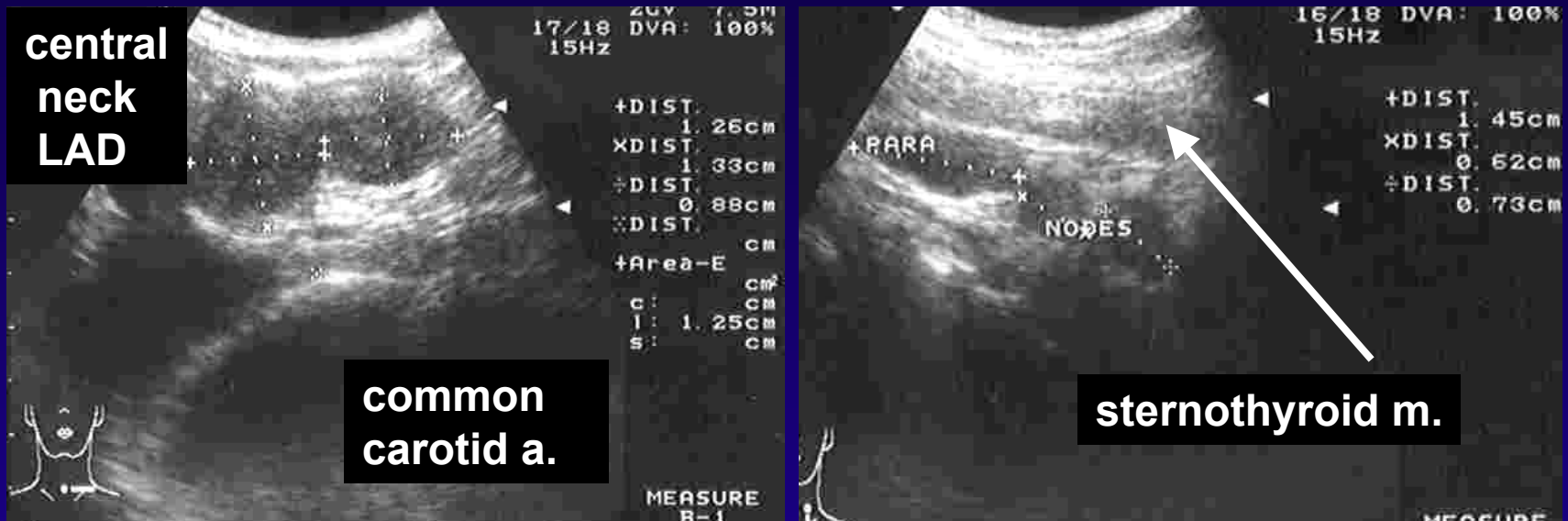
87/141 patients (62%)

- Identification of cervical lymphadenopathy pre-operatively
- Confirming cancer recurrence suspected by elevated Tg when standard imaging negative
- Incidental diagnosis of cancer in patients referred for HPT
- Clarifying thyroid etiology from complex clinical presentation



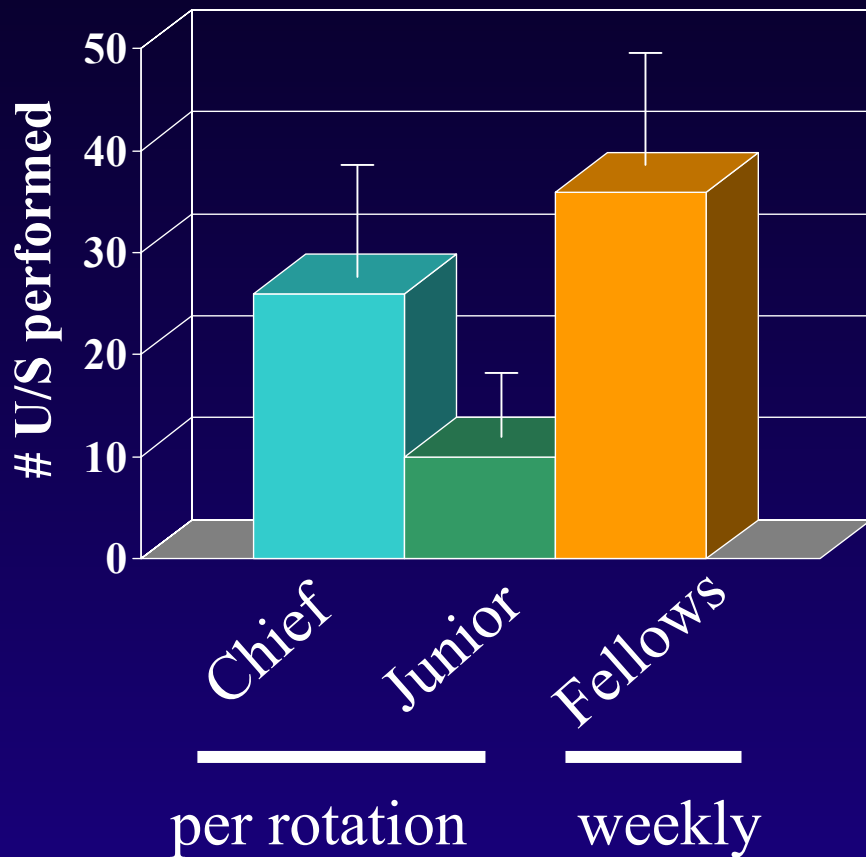
Results: Thyroid Cancer Diagnosis, Surgery & Surveillance

- U/S detected cervical lymphadenopathy in 45/141 (31%) patients
- Central and lateral neck compartments
- 19/45 (42%) patients with central neck mets at initial surgery





Results: Resident and Fellow Education



- **Individual U/S instruction \pm U/S course**
- **Perform U/S with interpretation in OR**
- **Thyroid U/S skills improve with > 10 U/S**
- **Parathyroid >20 U/S**

DATE _____
 PGY LEVEL _____

RESIDENT NAME _____
 1ST ULTRASOUND Y/N

RESIDENT/FELLOW		DR. MILAS/DR. SIPERSTEIN	
ANATOMICAL STRUCTURES		ANATOMICAL STRUCTURES	
Central View	<input type="checkbox"/> Trachea <input type="checkbox"/> Isthmus <input type="checkbox"/> Thyroid	Central View	Trachea Isthmus Thyroid
Right Neck	<input type="checkbox"/> Strap Muscles <input type="checkbox"/> Lobe <input type="checkbox"/> Carotid Artery <input type="checkbox"/> Jugular View Superior Thyroid A Inferior Thyroid A Thymus Vagus Esophagus	Right Neck	Strap Muscles Lobe Carotid Artery Jugular Veiw Superior Thyroid A Inferior Thyroid A Thymus Vagus
Left Neck	<input type="checkbox"/> Strap Muscles <input type="checkbox"/> Lobe <input type="checkbox"/> Carotid Artery <input type="checkbox"/> Jugular Veiw Superior Thyroid A Inferior Thyroid A Thymus Vagus <input type="checkbox"/> Esophagus	Left Neck	Strap Muscles Lobe Carotid Artery Jugular Veiw Superior Thyroid A Inferior Thyroid A Thymus Vagus
Lateral/Poserior Neck Muscles Submandibular Gland	Y/N	Lateral/Poserior Neck Muscles Submandibular Gland	Y/N
Lymphadenopathy Location	Location _____ Size _____	Lymphadenopathy Location	Location _____ Size _____

RESIDENT/FELLOW

DR. MILAS/DR. SIPERSTEIN

ENDOCRINE PATHOLOGY

ENDOCRINE PATHOLOGY

Thyroid Nodule #1 Location right
Size 1.7x1.3
Features complex

Thyroid Nodule #1 Location _____
Size _____
Features _____

Thyroid Nodule #2 Location _____
Size _____
Features _____

Thyroid Nodule #2 Location _____
Size _____
Features _____

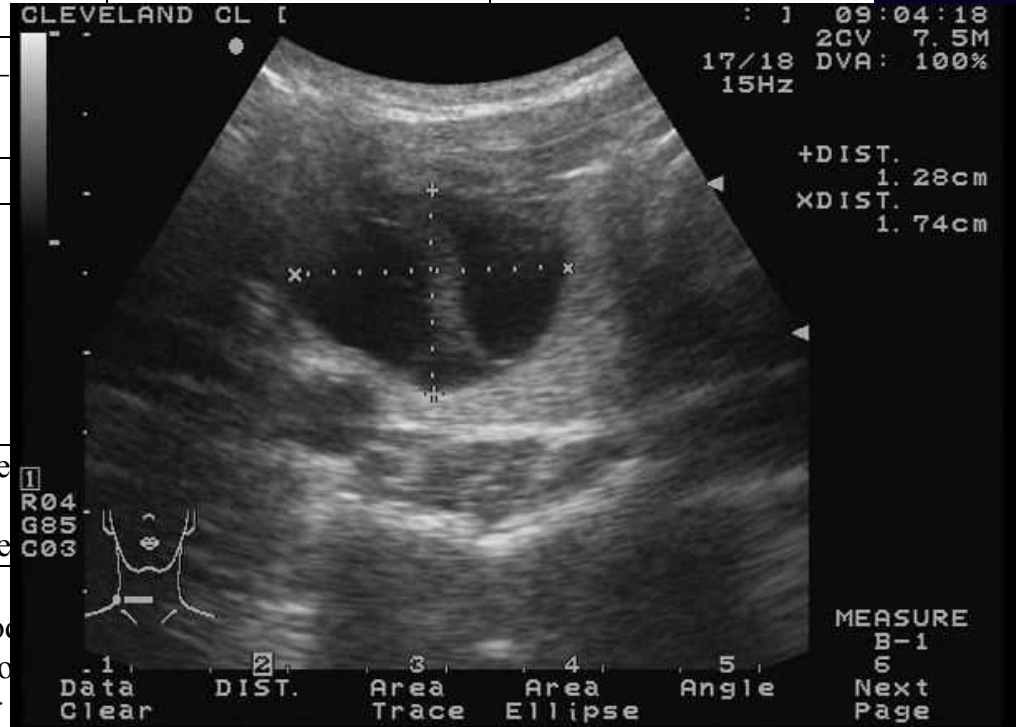
Thyroid Nodule #3 Location _____
Size _____
Features _____

DIAGNOSIS

Thyroid Normal
 Solitary Nodule
MNG
Diffuse Goiter
Malignancy
Thyroiditis

Parathyroid No Parathyroids Seen
Single Adenoma
Multigland Disease

Lymph Nodes None Seen
Normal Lymph Nodes
Enlarged lymph Nodes
LN Suspicious For
Metastatic Disease



Metastatic Disease



Surgeon-performed Neck U/S

- **Patient satisfaction with time-efficient management of endocrine work-up**
- **Focused, individualized informed consent**
- **Surgeon's control of OR schedule**
- **“Bonus” applications of intra-operative U/S**

U/S as extension of physical examination

Routine incorporation of U/S into clinical care



Conclusions

- **Surgeon-performed neck U/S is a highly specific tool for defining endocrine disease**
- **Accurate, informative, readily learned**
- **Enhances resident education & skills**
- **More comprehensive evaluation of thyroid/parathyroid problems**
- **Benefits patient care and surgical decisions**

Valuable adjunct to an endocrine surgical practice